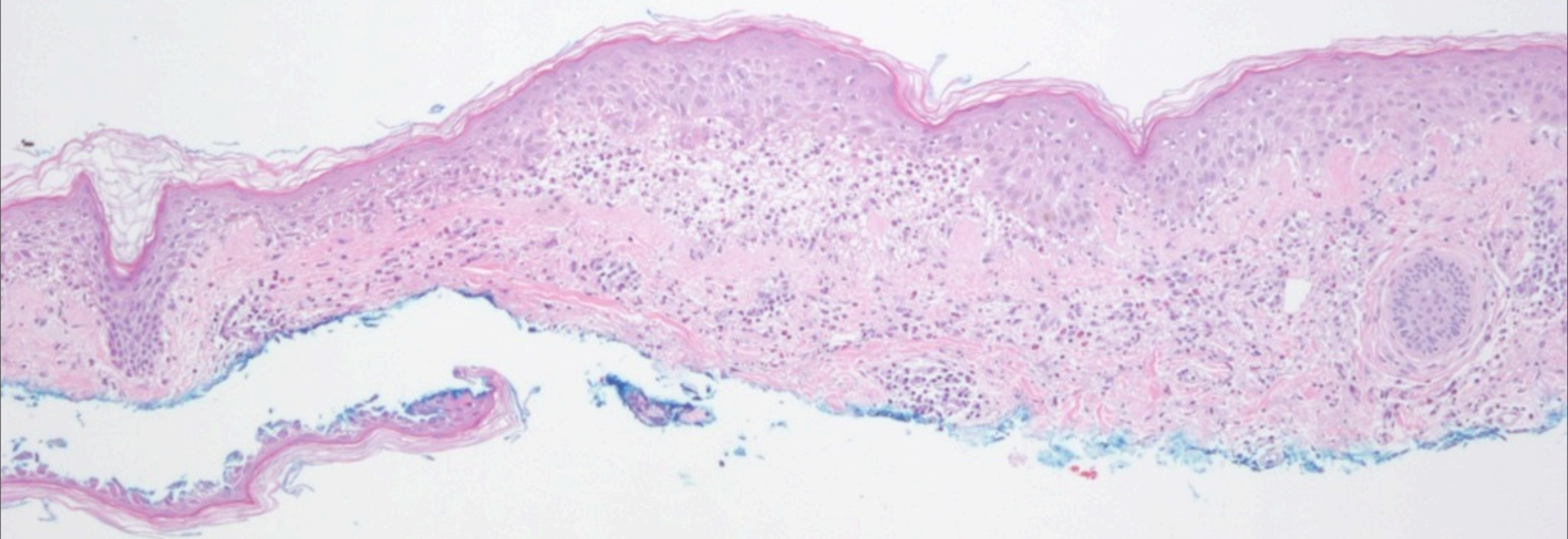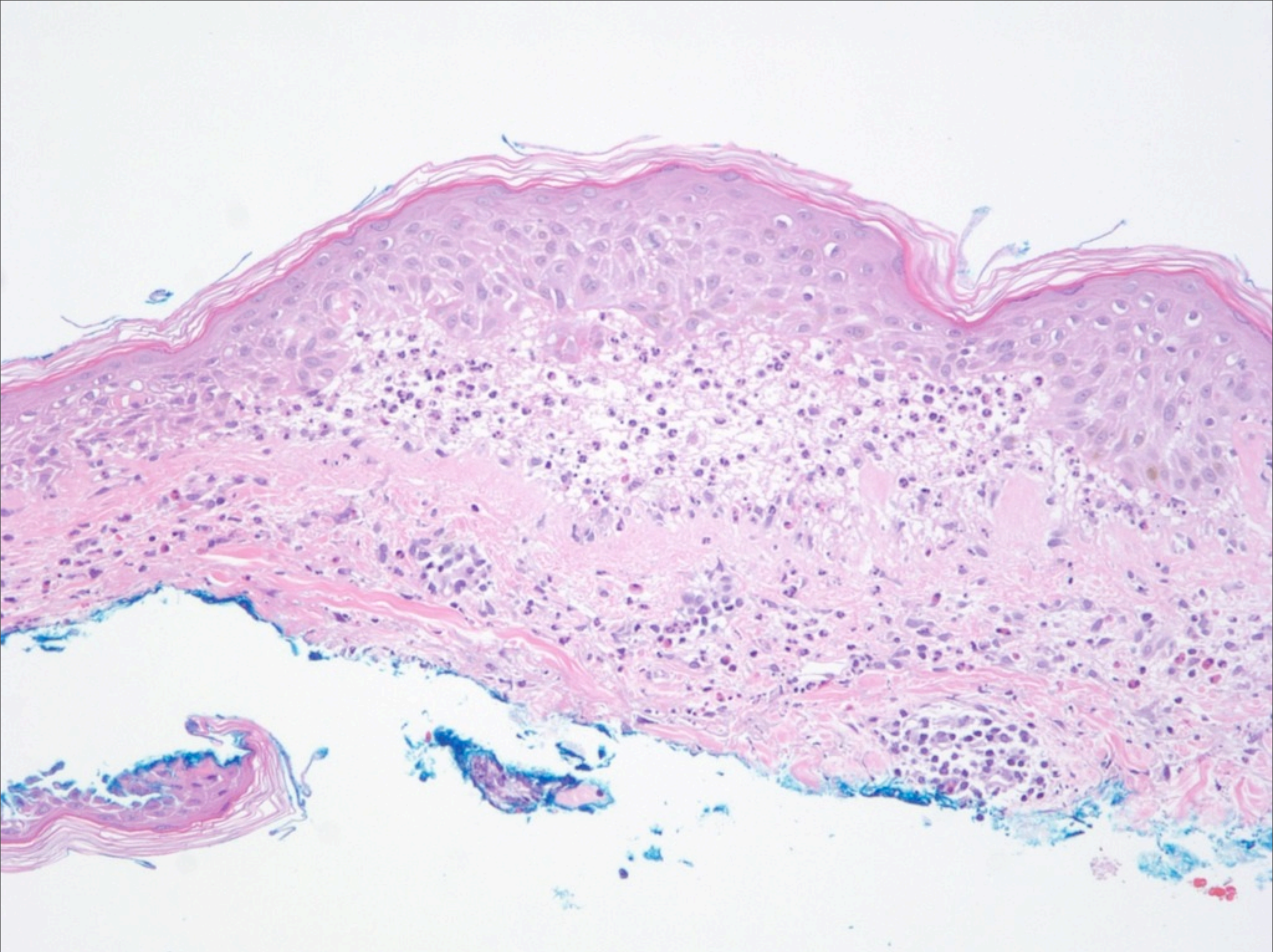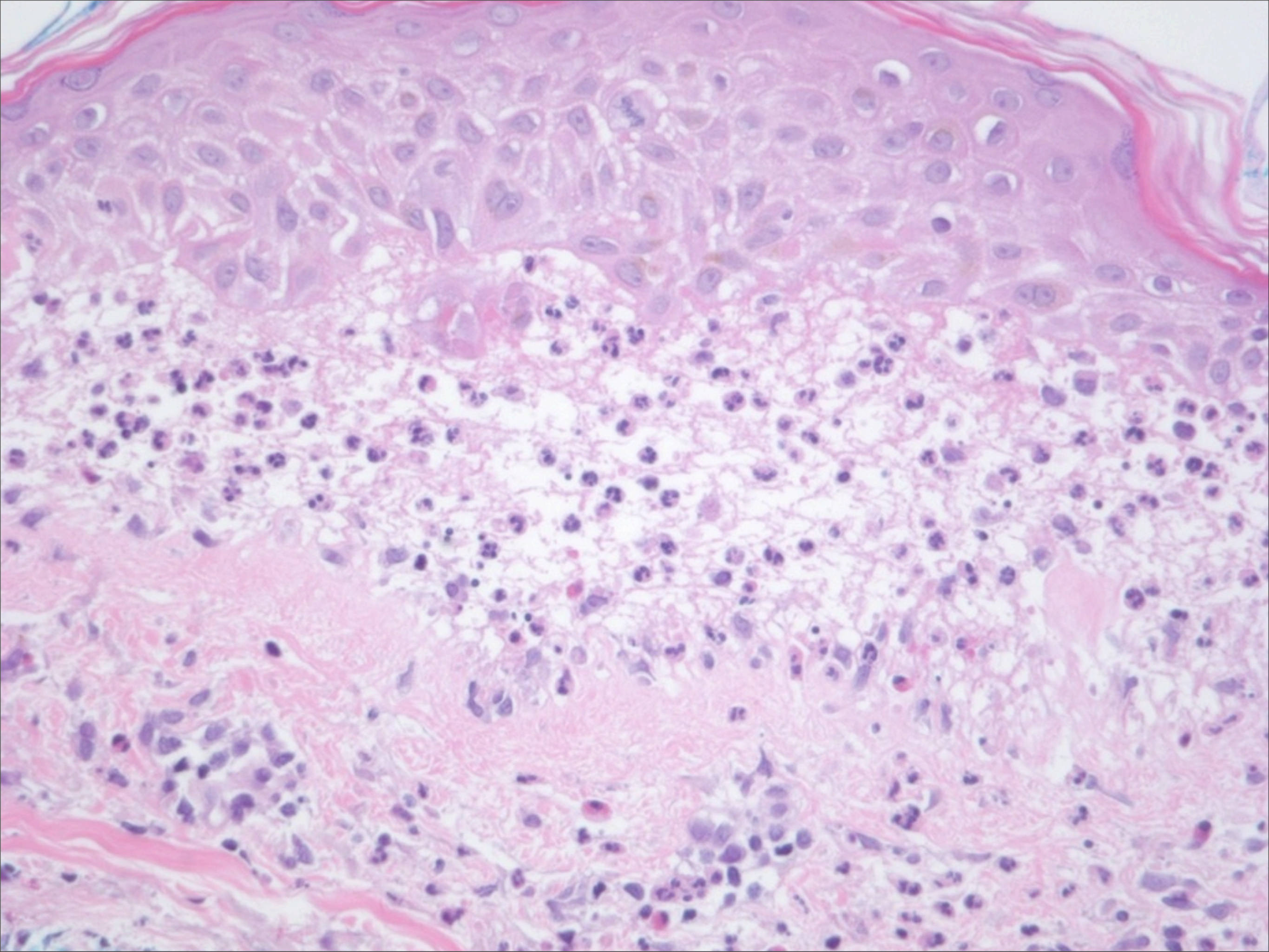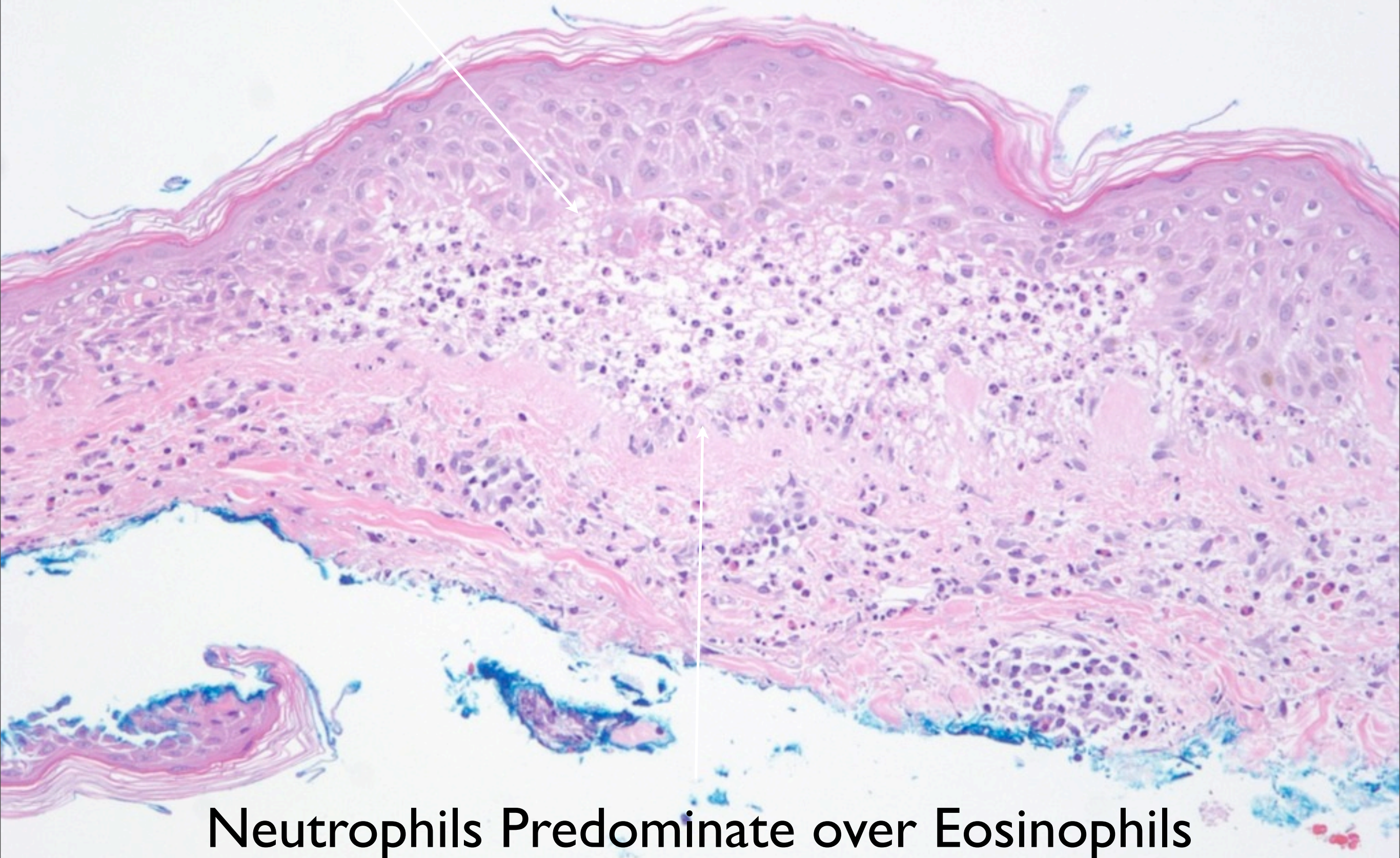


Linear IgA Disease

Notes

- DIF revealed linear deposit of IgA along DE junction

Papillary Dermal Microabscess



Neutrophils Predominate over Eosinophils